

Horses In Color: The Role of Thermal Imaging in the Equine Industry

Joanna L. Robson, DVM, CVSMT, CMP, CVA, SFT
Inspiritus Equine, Inc.
8 Golden Gate Circle
Napa, CA 94558
Ph: 707-738-7110

www.InspiritusEquine.com
Email: jrobsondvm@inspiritusequine.com

Abstract

Thermal imaging isn't new to the horse world, though it's finding its renaissance in today's performance-charged equine industry. As thermal camera technology has improved, and standardization in equine imaging is introduced, this diagnostic tool is finding its niche in equine veterinary practice and the horse industry as a whole. Thermal imaging is helping to identify and pinpoint hidden injuries and inflammation, aids in saddle-fitting, may prevent breakdowns and determine whether a horse is ready to compete, provides insight during pre-purchase examinations, and also benefits farriers and general practitioners. With trained technicians and veterinary interpretation, thermal imaging is finally taking its deserved place among traditional radiography and ultrasound as a useful, non-invasive, diagnostic modality. Thermal imaging provides a whole new vision of equine health.

Introduction

Thermal imaging was introduced to the equine industry in the 1960s, primarily as a screening tool for racetracks and performance horses. However, due to expensive and rudimentary cameras, little knowledge of correct imaging technique, and a lack of understanding of how to correctly interpret the images, the technology soon fell out of favor both with veterinarians and human medical professionals. In the 1980s, however, the U.S. courts accepted thermography as documented evidence of pain.¹ And while the American Academy of Orthopaedic Surgeons released an advisory statement in 1991 stating that: "A review of the literature indicates a lack of specificity, reliability, and reproducibility for this technique"², the use of thermography steadily continues to



increase in human screening for cancer, work-related injuries, and other physiologic processes. The use of thermal imaging is also increasing in the equine industry. So what has changed?

The Industry

The equine industry has undergone a major transformation over the past three decades. Now a multi-billion dollar industry with huge financial stakes both in and out of the barn, there is great demand for the latest and greatest in diagnostic equipment. There is also a more significant emphasis on alternative medicine and non-invasive modalities. Horse owners and trainers are well educated, and many expect the same quality of care for their animals that they would for their own human family members. “At the 1996 Olympic Games in Atlanta, where there was millions of dollars worth of equipment available to the equestrian teams, the most-requested diagnostic tool was thermography. It was fast. It was portable. It was non-invasive. It could detect injury sites before they became lameness problems, and could guide practitioners to specific anatomic areas for study using other diagnostic techniques. Also, it was extremely accurate when used by an experienced practitioner.”³ The demand for thermal imaging has boomed with the industry’s economic surge.

There are an estimated 9.2 million horses in the United States.⁴ The equine industry directly produces an average of 40 billion dollars annually, with the average GNP for the equine industry at 112 billion dollars or more!⁵ Consider that in addition to the buying and selling of horses, the equine industry also encompasses training and boarding,



trucks and trailers, competition revenue and sponsorships, entertainment, tack and equipment, feed, bedding, supplies, veterinary and dental care, alternative medicine modalities (acupuncture, chiropractic, bodywork, laser), farriery, and more. The average horse owner is a middle-aged Caucasian female, with an annual income of \$36,000-\$60,000 per year (range by state).⁶ Purchasing a horse may be free (adopting rescues) to millions of dollars (racehorse yearlings and proven performers). After the initial purchase, a horse owner may spend upwards of \$10,000 - \$30,000 per year to house, feed, train, and compete or ride her horse.⁷ The National Horse Council provides statistics on horse population and ownership.

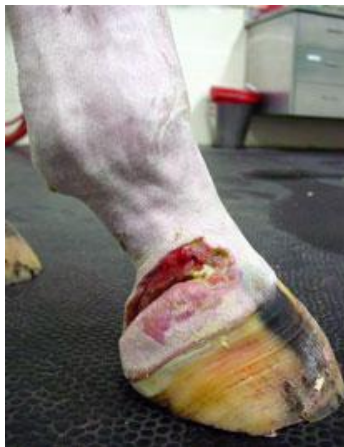Currently, the largest horse populations by state are Texas, California, Florida, and Kentucky, with other midwestern states on the rise.⁸ There are many different disciplines within the horse world. Dressage, show jumping, reining, cutting, polo, racing, endurance, roping, barrels, and halter are only a few examples of the many different equine sports world-wide. The Federation Equestre Internationale is the international governing body for all horse sport, and there are many national organizations divided by breed or discipline, as well as pony club and therapeutic riding programs.

Equine Health

In this high-stakes, financially and emotionally charged equine world, protecting and caring for our equine companions is of the utmost importance. The field of equine sports medicine is rapidly expanding with new advances in injury prevention, diagnosis, and treatment. In order to understand the ever-increasing role of thermal imaging in equine health, we must first examine the types of injuries we encounter in horses, and how they occur.



The horse is a prey animal, and though the small 3-toed prehistoric creature has evolved into the single-hoofed animal we know today, the flight response hasn't much evolved. "Horses have a very well-developed 'fight or flight' mechanism and when anything happens to startle them, they often react first and think later. If they get caught in something such as a fence or barn wall, their first instinct is to leave; often without regard to whatever body part happens to be caught at the time. Therefore, horses have a well-deserved reputation as being accident-prone."⁹ We have domesticated horses through the millenia for food and milk, packing, fighting wars, and transportation. But today's horse is predominantly used for sport and recreation, with heavy emphasis on churning out prospects and starting them at younger ages, making them more readily available for the sale barns. These animals, that are designed to be moving and grazing constantly, now find themselves limited to our artificial environment of a 10' x 10' box stall, twice daily feeding, and limited daily exercise. Horses, through flighty instinct, boredom, extreme size, great energy, increasing sports demand, and often fragile genetics, will injure themselves – it is only a question of when and how badly.



Laceration of the pastern.
From acvs.org.

Equine injuries could be subdivided into: accidental, human-induced, and physiologic or naturally occurring. Accidental injuries would include lacerations and scrapes, broken bones and soft-tissue injuries that occur as a result of a horse playing, falling or slipping, encountering sharp objects (broken fencing, nails, etc.), trailer traumas, or being kicked or injured by another horse. Human-induced problems include all those that are caused by our intentional or unintentional ignorance. For example, the soring of gaited horses (intentional application of a caustic substance to exaggerate a desired movement), ill-fitting tack and saddles, poor trimming and shoeing, imbalanced or forceful riding, and failure to recognize signs of early lameness that results in more significant disease and injury. Physiologic or naturally occurring diseases are those such as arthritis or kissing spine, laminitis (inflammation of the hooves), age-related changes (hormonal), cancer, or infections (EPM, EHV-1). These categories are often overlapping. Man's forceful riding on uneven ground will lead to

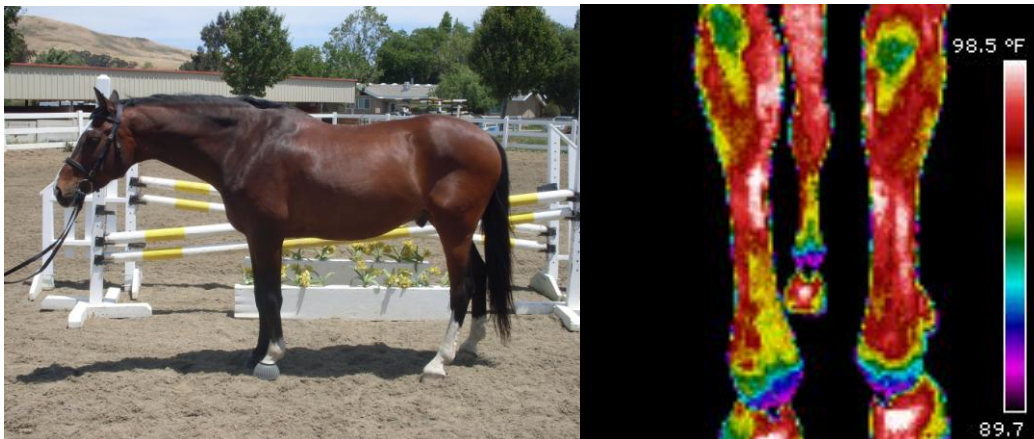
tendon and ligament tears, or early arthritis. Man's racing of a young horse with an undiagnosed hairline fracture, may result in a fatal "accidental" breakdown.

Some specific major common diseases or pathologies resulting in decreased performance, lengthy rehabilitation, or retirement include (List A):

- Suspensory ligament tears
- Tendon tears
- Sacroiliac problems
- Arthritis
- Muscle pulls, tears, strains, avulsions
- Damage from ill-fitting saddles and tack, imbalanced riders
- Kissing spine, other primary spinal lesions
- Fractures
- Cervical problems
- Nerve damage
- Circulatory problems
- Infection/abscess
- Hoof problems – ringbone, laminitis, imbalanced hooves

This list is important, as each of these problems causes circulatory or inflammatory changes that can be detected with a thermal imaging camera!

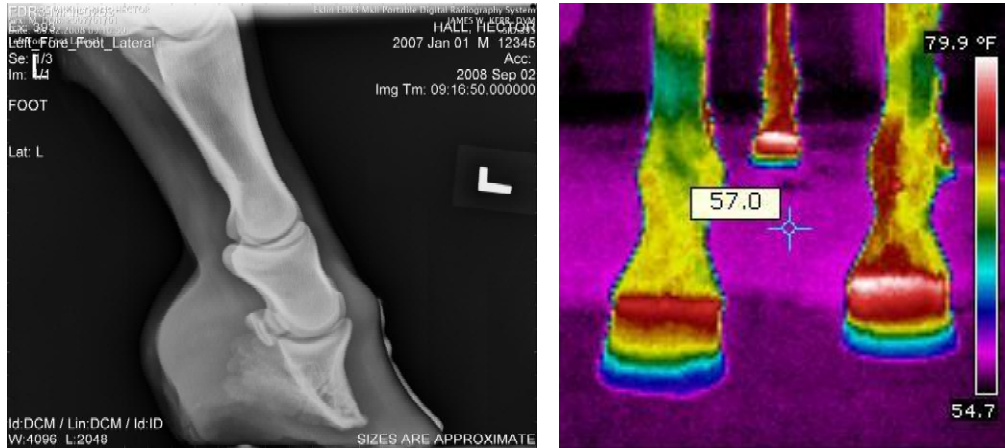
With the significant amount of time and money invested in the performance horse, any one of the above conditions can be catastrophic for both the owner and the animal. Advances in veterinary medicine have resulted in significantly improved detection and treatment of these diseases, but at a generally significant financial and emotional cost to the owner. Why? Because *current diagnostic modalities are aimed at diagnosing the problem once it has started and lameness is detected*. But, PREVENTION and early detection are the keys!



Below: "Laddie" has a lameness, but his owner is unsure of how to proceed with diagnostics to determine where and what the problem is. Thermal imaging scan reveals bilateral heat increase on the hindlimbs, which is then diagnosed with ultrasound as bilateral suspensory ligament disease.

The Modalities

The major difference between traditional diagnostic modalities, such as ultrasound, and thermal imaging, is that one is *anatomic*, while the other is *physiologic*. An anatomic diagnostic modality will show a specific lesion or problem in an anatomic structure at a static moment in time. A physiologic modality such as thermal imaging cannot show a specific anatomic lesion, but does show a physiologic change in bloodflow that helps to localize a lesion and more easily shows changes over time. Let's examine the diagnostic modalities currently available, and how they compare.



Above Left: On the left is a radiograph of a horse with a club foot. This is an “anatomic” modality as radiographs show a specific anatomy and pathology. **Above Right:** A thermal image of a horse’s front feet, showing a “physiologic” difference in the circulatory patterns between the two.

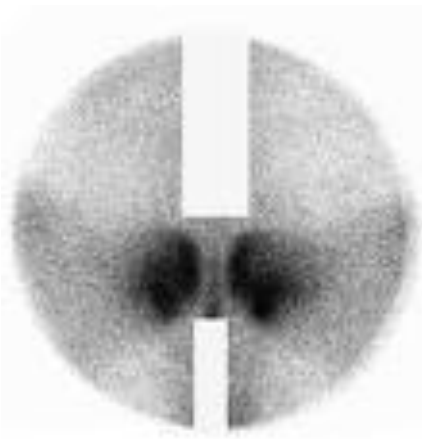
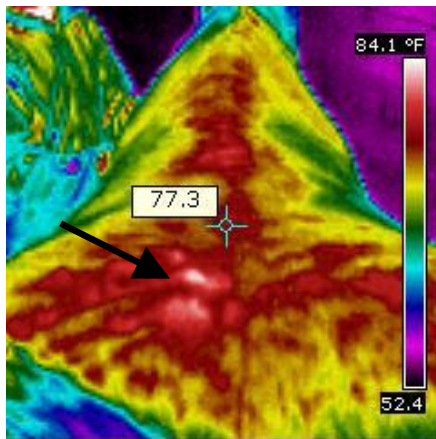
Table 1 below illustrates the modality, what problems it detects, average cost in dollars, and advantages and disadvantages of each.

Table 1

Modality	Detection	Cost	Advantage	Disadvantage
MRI	Soft tissue and bone	\$1200-\$3000	Specific, anatomic	Expensive, requires anesthesia
CT	Soft tissue and bone	\$1200-\$3000	Specific, anatomic	Expensive, requires anesthesia
Nuclear scintigraphy	Bone and some soft-tissue structures	\$500-\$2000	Whole body, sensitive, physiologic	Not specific, will require follow-up diagnostics; usually 3 days in hospital, invasive
Ultrasound	Soft tissue, some bone	\$100-\$300 per region	Specific, anatomic	Limited by region, may require sedation and clipping
Radiographs	Bone, some soft tissue (if swollen or affected)	\$100-\$300 per image or region	Less expensive, good quality now with digital radiographs	Limited by region, may require sedation, radiation exposure
Thermography	Bone and soft-tissue	\$100-\$300 for total body scan, often includes veterinary interpretation	Full body evaluation, non-invasive, early detection of problems BEFORE clinical signs, Physiologic	Correct preparation is necessary for a good evaluation; artifacts may alter images, often requires follow-up diagnostics
Veterinarian's lameness evaluation	General	\$150 plus regional blocks	Considered the standard "first step", important general baseline	Often requires follow-up diagnostics, not always sensitive or specific

Based on the table above, we can see that thermal imaging stands out as one of only 2 whole body modalities, and is by far the most cost-effective whole body imaging available. Thermography is non-invasive, and is also the most effective "preventative" modality through its ability to detect temperature changes indicative of early inflammation or circulatory disruption. In fact, thermal imaging has repeatedly demonstrated signs of soft-tissue injury, such as tendon or ligament damage, two weeks BEFORE any clinical signs of lameness, or heat or swelling were detected.¹⁰

Thermal imaging should be considered as much a diagnostic tool, as it is a preventative maintenance tool. As mentioned in the introduction, the human medical field has routinely rejected thermography because of the need for, and ready availability of, specific imaging modalities (MRI, CT, etc.). However, in the equine industry, general anesthesia carries inherent risks, and while most clients want the best for their horses, expense does play a role in the diagnostic process. Equine insurance companies will often cover thermographic imaging, which also makes it a more accessible tool to horse owners.

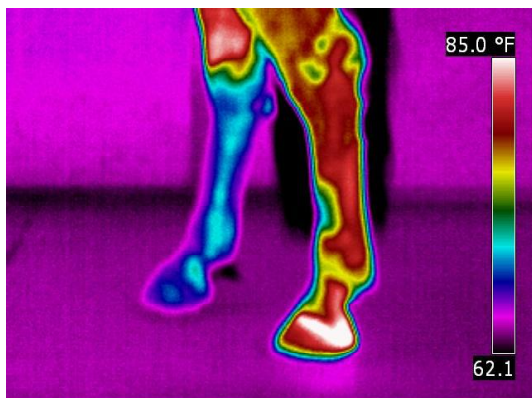


Above: Image at left is a thermal scan showing increased heat over the sacroiliac/tuber sacrale region of a horse (arrow). At right is a nuclear scintigraphy image of the same region on a different patient (from Langfordvets.co.uk)

Roles of Thermography

Thermal imaging is useful throughout the equine industry, but the tool finds its niche in a few key areas: injury detection and prevention, pre-purchase evaluations, saddle-fitting, and farriery.

The injuries and diseases listed earlier produce inflammation or changes in bloodflow that are directly related to radiant heat emitted from the body surface. Likewise, a lack of circulation may also be an indicator of disease, and muscle atrophy, nerve damage, scar tissue, and circulatory disruption may also be detected with thermal imaging.

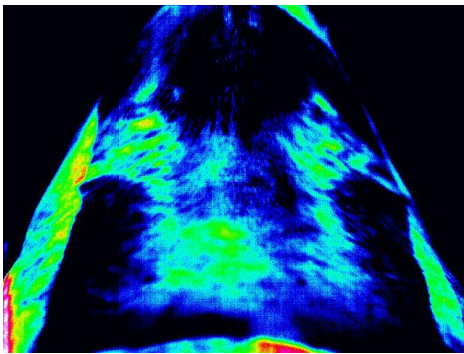


This horse had NO outward signs of lameness. The “blue leg” is a significant circulatory or nervous system abnormality. Without thermography, how would this ever be discovered?

Pre-purchase evaluations are often a veterinarian’s nightmare. Making decisions about whether or not a horse is suitable for purchase based on a general physical examination, radiographs of specific joints, and perhaps an endoscopy, misses a large percentage of the patient – all the soft tissues

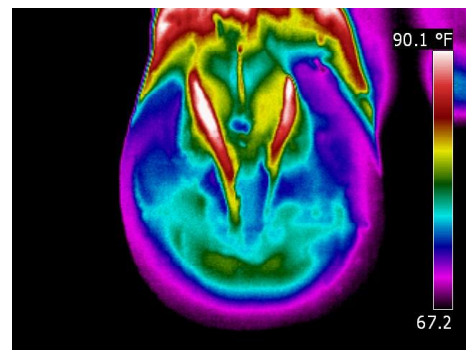
and regions that cannot be palpated or evaluated with a traditional modality! Professional reputations are at stake, and equine malpractice insurance premiums are through the roof as horse purchase prices soar. Utilizing a non-invasive WHOLE BODY scan as part of a pre-purchase evaluation to determine whether there are other “hidden” lesions present can make a significant impact on the buying and selling of horses. Thermography has the potential to become a standard practice in the equine buying and selling game due to its being non-invasive and generally inexpensive. The cost-to-benefit ratio of the scan in a pre-purchase evaluation is one of its greatest attributes.

Saddles and equipment play a significant role in equine performance. Imagine running a marathon in shoes two sizes too small – ouch! Now explain to a horse how he’s going to jump a 6-foot-high brick wall in a saddle that vice-grips his shoulders! Many clients need the objective image evidence of the inflammation that is caused by their ill-fitting tack to be spurred into making positive changes, especially when the sales representative has “assured” them of a correct fit. Rider balance also plays a significant and often under-discussed role in equine performance. Thermal imaging can help to demonstrate the difference between the influence of tack, and the influence of an imbalanced rider, on the horse beneath.



Left: Thermal image of a horse’s back during a saddle-fitting seminar. The saddle put increased pressure over the left side of the horse’s back, and impinged on the left thoracic spine. Thermography is a useful saddle-fitting tool, but should be combined with a certified saddle-fitter for best results.

Farriers are also taking great notice of thermal imaging capabilities. From evaluating hoof imbalances, to diagnosing laminitis and abscesses, this tool can help to stage disease or locate problems. Navicular syndrome and laminitis both have a huge financial impact on the equine industry, and thermal imaging is playing a role in the research of both diseases.




Other thermal imaging niches include track and arena footing scans, and the eliminating of soring and other unethical practices (tail blocking, nerving, etc.). The FEI currently sanctions thermal imaging as a tool to determine whether a horse is fit to compete, or if its legs have been tampered with.

Success with Thermal Imaging

What are the most important factors for success with equine thermal imaging? Standardization and correct interpretation are crucial to the continued acceptance of thermal imaging as a diagnostic modality. Thermal imaging failed in its inception in the equine industry because of a lack of standardization and understanding of the technology and its correct use. Thermal imaging was compared to radiographs and ultrasound, which could show specific lesions; and was therefore discarded because of its lack of specificity. Now, with significantly better technology and recognition of the importance of standardization, thermal imaging is taking its rightful place in equine diagnostics.

Standardization and correct patient preparation are *imperative* to both minimize artifacts, and to maximize gain through bloodflow and residual inflammation (or lack thereof). Artifacts such as moisture and sweat, dirt, caustic substances, bandages and blankets, can and will immediately negate the correct interpretation of a scan. Environmental control cannot be over-emphasized as critical to a successful scan. Sunlight, radiant heat from metal roofs or barn siding, fans and breezes, and the flooring of the barn (mats, dirt, concrete, etc.) can alter images and destroy a scan. Having a clean and dry patient in an environment free of drafts, direct sunlight or moisture, are keys to the success of your imaging scan, and to the repeatability and reliability that thermal imaging requires for continued acceptance in the veterinary and equine industries.

Interpretation of the images is the other half of a successful imaging equation in a modality dependent on symmetry. In keeping with state veterinary practice laws, thermal imaging interpretation must be done by a licensed VETERINARIAN. Even



more important, in addition to a solid understanding of patient anatomy, an interpreting veterinarian must have an understanding of thermal imaging technology to correctly relate the images with possible physiologic changes. Of all the injuries bulleted in List A, thermal imaging is able to locate every one through physiologic changes emitting heat or altered circulation. Though the images are not able to tell the interpreter the specific nature of the lesion, the sensitivity of the camera to detect

temperature changes related to disease is key to its success. Changes greater than 1-2 degrees F are considered significant¹¹, but asymmetry and a deviation from normal anatomic structures are major factors in image interpretation.

Conclusion

Thermal imaging is a diagnostic tool that is gaining more widespread interest and recognition in the equine industry. Infrared camera technology has significantly improved, and understanding the technology is leading to improved interpretation of thermal imaging in biological systems. It is incorrect to tout thermal imaging as a replacement for traditional diagnostics. Thermal imaging's strength is that it can significantly enhance traditional modalities through improved localization of injury and disease, and has an adjunctive role in highlighting lesions otherwise missed with traditional imaging modalities.

Correct training is imperative. To learn more about adding equine thermal imaging to your business, please visit www.equineir.com to view their training modules.

References

1. Strickland, C. Thermography: A hot images and a hot topic. *The Horse*, Oct 2001, 853
2. Ibid
3. Brown, K. Thermography: Diagnosis tool for horses. *The Horse*, Oct 2001, 490
4. National economic impact of the US horse industry, www.horsecouncil.org
5. Equine nutrition and health. www.alltech.com
6. www.horsecouncil.org
7. Ibid
8. Ibid
9. ACVS General Wound Management www.acvs.org
10. Brown, K. Ibid
11. Ibid

For more resources on thermography in the equine industry, please visit www.thehorse.com or www.pubmed.com and search "equine thermography".